

Paediatric airway management: basic aspects

R. J. HOLM-KNUDSEN and L. S. RASMUSSEN

Department of Anaesthesia, Center of Head and Orthopaedics, Copenhagen University Hospital, Rigshospitalet, Copenhagen, Denmark

Paediatric airway management is a great challenge, especially for anaesthesiologists working in departments with a low number of paediatric surgical procedures. The paediatric airway is substantially different from the adult airway and obstruction leads to rapid desaturation in infants and small children. This paper aims at providing the non-paediatric anaesthesiologist with a set of safe and simple principles for basic paediatric airway management. In contrast to adults, most children with difficult airways are recognised before induction of anaesthesia but problems may arise in all children. Airway obstruction can be avoided by paying close attention to the positioning of the

head of the child and by keeping the mouth of the child open during mask ventilation. The use of oral and nasopharyngeal airways, laryngeal mask airways, and cuffed endotracheal tubes is discussed with special reference to the circumstances in infants. A slightly different technique during laryngoscopy is suggested. The treatment of airway oedema and laryngospasm is described.

Accepted for publication 21 August 2008

© 2008 The Authors
Journal compilation © 2008 The Acta Anaesthesiologica Scandinavica Foundation

AIRWAY-RELATED problems are among the most common perioperative critical incidents in paediatric anaesthesia, and in infants younger than 1 year of age these are four times more common than in older children.¹ Knowledge about and training in paediatric airway management is therefore mandatory.

The purpose of this paper is to describe some of the differences between the paediatric and adult airway and to suggest principles for basic paediatric airway management, covering positioning, mask ventilation, inhalational induction, use of supraglottic airways, endotracheal intubation, and tracheal extubation. The prevention and treatment of airway oedema and laryngospasm are also described. Even small changes in the practical management can make a huge difference and it is the aim of this paper to supply the non-paediatric anaesthesiologist with some useful practical hints that may provide a set of safe and simple principles.

Preparation and pre-operative evaluation

A careful medical history related to airway problems should be obtained before anaesthetising a

child. The parents may have observed signs of a difficult airway such as excessive snoring and sleep apnoea, or they may present a history of problems during previous anaesthesia. In contrast to adults, most children with difficult airways are recognised before induction of anaesthesia. Syndromes with face malformations, especially those with a short mandible and ear deformity, should alert the anaesthetist, as these are often associated with difficult airways.

Differences between the paediatric and adult airway

The airway in infants and small children is very different from the airway in older children and adults. Obviously, the size is smaller, which itself may make things slightly more difficult, but other factors must also be taken into consideration during airway management in small children as summarised in Table 1. The difficulties can result in airway obstruction and apnoea. Unfortunately, the oxygen reserve is much smaller because of a low functional residual lung capacity and higher oxygen consumption. Desaturation therefore occurs much more rapidly.

Table 1

Differences between the adult and paediatric airway.

Dimensions smaller
Head relatively larger in infants
Tongue relatively larger
Short Jaw
Palate long
Long Epiglottis
Larynx located more cephalad
Vocal cords angled more anteriorly
Airway narrowest at the cricoid cartilage
Airway soft
Airway more reactive and infants more prone to develop laryngospasm.

Positioning

Head positioning is extremely important during airway management in small children. The optimal position is obtained when the neck is in a neutral or a slightly extended position (Fig. 1). The head, and especially the back of the head, is relatively large, and the younger the child is, the more pronounced this is. Therefore, in neonates and premature children, airway management should be performed with a small towel under the shoulders to avoid flexion of the neck. A foam ring to stabilise the head may cause neck flexion that makes airway management more difficult, but this can be compensated for by placing gel pads or similar objects under the back of the child.

Mask ventilation

Many different types of face masks are available on the market. A transparent, disposable mask with a large and soft cuff is recommended, as this feature makes it very easy to establish an airtight seal to the face. At the same time, the transparency is useful, and the children seem to find them less frightening than the black masks. It is important to choose a face mask large enough to allow the mouth of the child to be open during ventilation, but at the same time the mask should not cover the eyes of the child (Fig. 2). The tongue falls back when the child is anaesthetised and this tends to obstruct the airway. Obstruction is best avoided if the mouth is kept open during mask ventilation. This is accomplished by pressing the distal cuff of the mask against the chin. No pressure should be applied against the floor of the mouth, as this will press the tongue against the palate and airway obstruction may result.

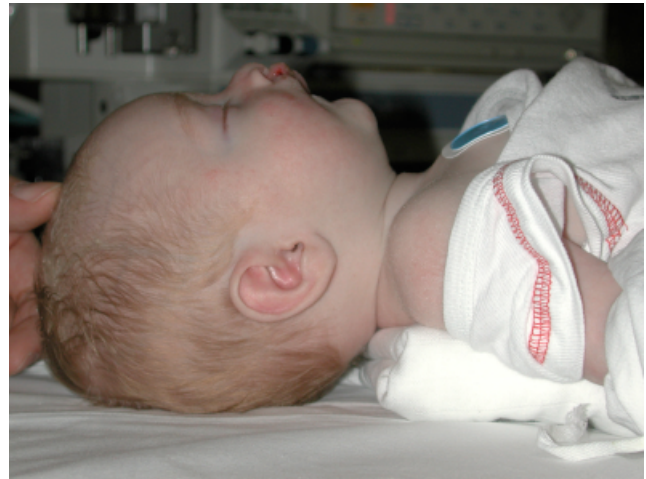

Fig. 1. The optimal position for airway management is with the head in a neutral or slightly extended position. In premature children, a small towel under the shoulders is helpful.

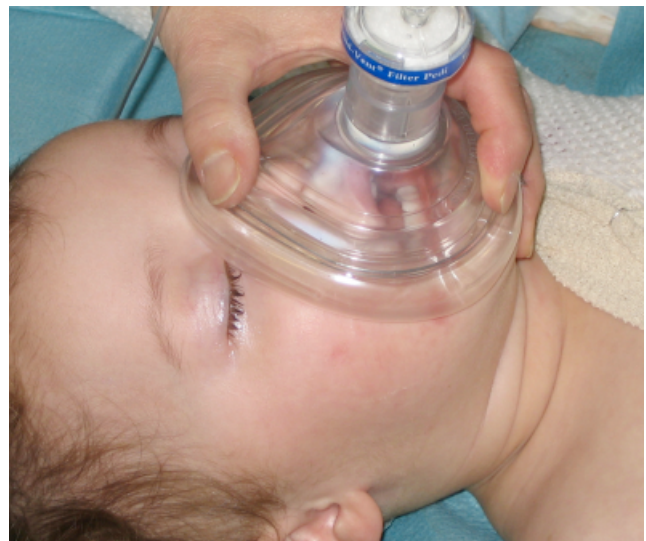

Fig. 2. The face mask should be large enough to allow the mouth of the child to be open during ventilation, but at the same time it should not cover the eyes of the child.

It may be helpful to show the face mask to the child before mask induction. If the mask is waved in front of the infants, their natural instinct is to grab for the mask and 'taste' it, thereby facilitating induction.

The older child may realise that the face mask is not that scary, and most of the older anxious children feel safer, and they may cooperate better, if they hold the face mask themselves. In anxious children, it is recommended to initially administer 70% nitrous oxide in oxygen, while telling a story as a 'fantasy journey'. The 'fantasy journey' is an

interactive story in which the child participates (e.g. riding a bike or a motorbike or swimming among dolphins). After a couple of minutes, sevoflurane 0.2–0.3% is added for 20–30 s, after which, the concentration can be quickly increased to 6–8%.

Airway muscle tone is always decreased during inhalational induction and some degree of obstruction frequently occurs. Twisting movements of the extremities are often an early sign of partial airway obstruction, and the basic technique should be reviewed; i.e. head position, open mouth, and no pressure under the chin. A chin lift or a jaw thrust may be helpful. The mouth of the child should be opened widely if airway obstruction is not immediately relieved. Quite often, it will be observed that the tongue is pressed against the palate and the wide mouth opening will release the tongue from the palate and restore the open airway.

Some children continue to obstruct despite a correct technique. This is most commonly seen in children who also obstruct during sleep. This may be caused by hypertrophic tonsils, airway malacia, or other conditions with narrow or soft airways. In these children, it is useful to apply assisted ventilation with CPAP, 10–15 cm of water, by slightly squeezing the ventilation bag during the expiration phase, thereby expanding the airway.

If the described techniques are used, supraglottic airway devices are rarely needed. An oral or a nasal airway may be used, but the risk of eliciting a laryngospasm should be kept in mind. The detection and management of laryngospasm is described later.

Gastric air insufflation is very common during mask ventilation in infants, and the stomach should always be emptied after mask ventilation. This is especially important if ventilation has been difficult or the anaesthesiologist is not very experienced with ventilating small children. Severe gastric distension grossly impairs the movement of the diaphragm and ventilation may be almost impossible if this occurs. In this situation, the stomach must be vented to allow adequate ventilation. In premature infants with low lung compliance, mask ventilation may easily be accomplished by using small tidal volumes and a very high respiratory rate.

Supraglottic airway devices

An oral airway prevents the tongue from pressing against the palate and creates a passage for ventilation. It is important that the oral airway has exactly the correct length, which is estimated by holding it

against the cheek of the child. The tip of the airway should reach distal to the angle of the jaw. If the oral airway is too short, it will displace the tongue and obstruct the airway, and if it is too long, it may precipitate laryngospasm, as anaesthesia is often light, when the oral airway is needed. As mentioned earlier, if the mouth is kept open during mask ventilation, the oral airway is only rarely needed.

A nasopharyngeal airway rarely causes laryngospasm, even if it is inserted during light levels of anaesthesia. Ordinary uncuffed endotracheal tubes are most useful. The advantage is the possibility to connect the anaesthetic circuit directly to the 'nasal airway' when in place. It is advisable to use a suction catheter as a guide, when the nasal airway is passed through the nose, to avoid bleeding. The size of the 'nasal airway' should be smaller than when used for endotracheal intubation. Size 3.0 is appropriate in newborns, and nasal airways >4.5 or 5.0 are not necessary for this purpose even in larger children. The optimal insertion depth is estimated by listening to the breathing sounds in the 'nasal airway'. In the first year of life, this depth is 8 ± 0.5 cm and in the second year it is 8.5 ± 0.5 cm.²

The nasal airway is also a useful device in difficult upper airways or in the case of a difficult face mask fit.² It is possible to assist or control ventilation via the nasal airway if the mouth and the free nostril are closed manually.

Laryngeal mask airways (LMA)

LMA are widely used in children. In many situations, it is an acceptable alternative to endotracheal intubation and its usefulness in difficult airways is well documented. The choice of the LMA is based on the lean body weight of the child (Table 2). The LMA is usually easy to insert in children, but in infants the long epiglottis is frequently caught and down-folded by the tip of the LMA. Therefore, many paediatric anaesthetists prefer to insert the smaller LMA in a reverse fashion, with the opening

Table 2

Laryngeal mask airway sizes.

<5 kg	#1
5–10 kg	#1.5
10–20 kg	#2
20–30 kg	#2.5
30–50 kg	#3

of the mask against the palate, and then rotate it in place when it is fully inserted.³ This technique can only be used in LMA with a rigid tube. It is common to inflate the cuff partly during insertion. The amount of air in the cuff should keep it expanded but not distended. When the LMA is in place, the pilot cuff should be soft, and aspiration of some of the air may be needed, but with this technique, it should not be necessary to inflate the cuff further. If there is a leakage around the LMA, it is probably misplaced or too small. It is important to make sure that the LMA does not displace from the central position. Otherwise, the risk of air insufflation of the stomach increases during controlled ventilation.⁴ Displacement and airway obstruction occur most frequently with the smallest LMA, and size #1 should probably only be used for short procedures by experienced users.⁵ Tracheal intubation is preferred with longer procedures. So far, it seems wise not to connect a ventilator, when the smallest LMAs are used. We do not use a ventilator when a size #2 LMA or less is used, corresponding to children weighing <20 kg. At the end of anaesthesia, the child is positioned on the side if possible. When spontaneous ventilation is sufficient the LMA is removed. If the cuff is not deflated before removal, more secretions are removed with the mask. The timing of removal is debated, but it is recommended to remove the LMA rather early, before the return of reflexes.

Endotracheal intubation

When infants and small children are intubated, several conditions differ from older children. The tongue is relatively large and takes up more of the space in the oral cavity. At the same time, the jaw is shorter, making it more difficult to displace the tongue. The larynx is located higher in the neck, and in newborns the laryngeal inlet is as cephalad as the second cervical vertebra.

The epiglottis is long, narrow, omega-shaped, and angled into the lumen of the airway covering the laryngeal inlet. This and the cephalad position of the larynx often make it difficult to visualise the laryngeal inlet by conventional laryngoscopy. The high location of the larynx also means that ‘the sniffing position’ is of no benefit in small children, and a pillow under the large head only makes airway management more difficult by flexing the neck. During the first years of life, the larynx moves distally until the age of four, when it is located at the adult level at C5–C6.

Until the age of 10–12 years, the narrowest portion of the airway is at the level of the cricoid cartilage, which is a ring of cartilage, which is why the airway at this point is rigid and not distensible. Therefore, an endotracheal tube that easily passes the vocal cords may still be too large, and forcing it through the cricoid ring will compress and traumatise the mucosa. The airway in small children is very vulnerable, and airway oedema and post-intubation stridor is easily induced. Subsequent tracheal scarring and stenosis may follow, although this is very uncommon.

Airway trauma can be reduced by careful instrumentation and by using an endotracheal tube of an appropriate size. The tube must not be forced into the trachea, and if a cuffed tube is used, the cuff pressure should be monitored and kept as low as possible. If a cuff pressure >30 cm of water is necessary to avoid leakage of air, changing to a larger tube should be considered. The tube should be firmly secured to avoid the tip of the tube to move up and down in the trachea. Likewise, movement of the head should be minimised.

In the smallest children, airway oedema will have the most impact due to the smaller dimensions.

The estimated size of the endotracheal tube can be chosen from a table (Table 3) and compared with the distal phalanx of the fifth finger of the child, which often correlates well with the tube size. From the age of 2 years, the formula Tube size = 4+(age/4), may be used as guidance. If cuffed tubes are used, the formula is changed to 3.5+(age/4).

The use of cuffed tubes has been shown to result in fewer reintubations due to ill-fitting tubes, and it is not associated with more cases of post-intubation stridor, as long as cuff pressure was monitored and kept as low as possible.⁶ For laryngoscopy two main types of laryngoscope blades exist: the straight, Miller-type blade or the curved MacIntosh-type blade. Both types may be used in the same way and the type chosen is a matter of preference. The MacIntosh blade can be used in children weighing >2–2.5 kg. The smaller size of

Table 3

Endotracheal tube sizes.		
	Uncuffed	Cuffed
Newborn <3 kg	3.0	–
Newborn	3.5	3.0
4 months	4.0	3.5
12–16 months	4.5	4.0

the Miller blade is an advantage in children below this weight.

Because of the long epiglottis and the cephalad location of larynx it is usually necessary, during the first year of life, to apply external pressure on the neck to bring the laryngeal aperture into vision. The exact location and force of pressure needed cannot be explained to an assistant, and you should be able to apply this pressure yourself by using the fifth finger of the hand holding the laryngoscope. To do this it is crucial not to hold too distally on the handle. The palm of the left hand should rest on the head of the child, and the first finger should not touch the handle of the laryngoscope, but be placed on the proximal end of the blade. In this way, the fourth and fifth finger can easily be used to apply pressure in the right place on the neck of the child, while the second and third finger may be used to support the handle (Fig. 3).

During laryngoscopy, the tongue should be moved to the left by the laryngoscope and the blade should be introduced gradually into the midline until the epiglottis is seen. The tip of the blade is then advanced further against the vallecula at the base of the epiglottis. The best view would often be like in Fig. 4A, where the epiglottis is covering the laryngeal aperture. Even though the Miller blade was designed to lift up the epiglottis, this should not be done routinely, as it may precipitate bradycardia. Instead, an external pressure may be applied over the larynx with the fifth finger, which will flip up the epiglottis and bring the vocal cords into view (Fig. 4B).

When the vocal cords are visualised, the endotracheal tube is inserted between them, and with-



Fig. 3. Laryngoscope grip in order to be able to apply pressure on the neck with the fifth finger. The first finger should not touch the handle of the laryngoscope, but be placed on the proximal end of the blade.

out use of force, it is then moved through the cricoid cartilage. In infants, the vocal cords are angled more anteriorly, and if the tip of the tube is caught in the anterior commissure, a slightly rotating movement of the tube will often solve the problem. It is important not to obstruct the view to the larynx during intubation to be able to visually control how far into the trachea the tube is inserted. As soon as the tube is in place, the centimetre marking near the gingiva or teeth is noticed. In this way, it is possible to re-establish the position of the tube, if it is accidentally moved during fixation. In premature children or other situations when a very accurate location of the tip of the endotracheal tube is critical, another technique may be helpful. During ventilation, the endotracheal tube is slowly advanced further, while at

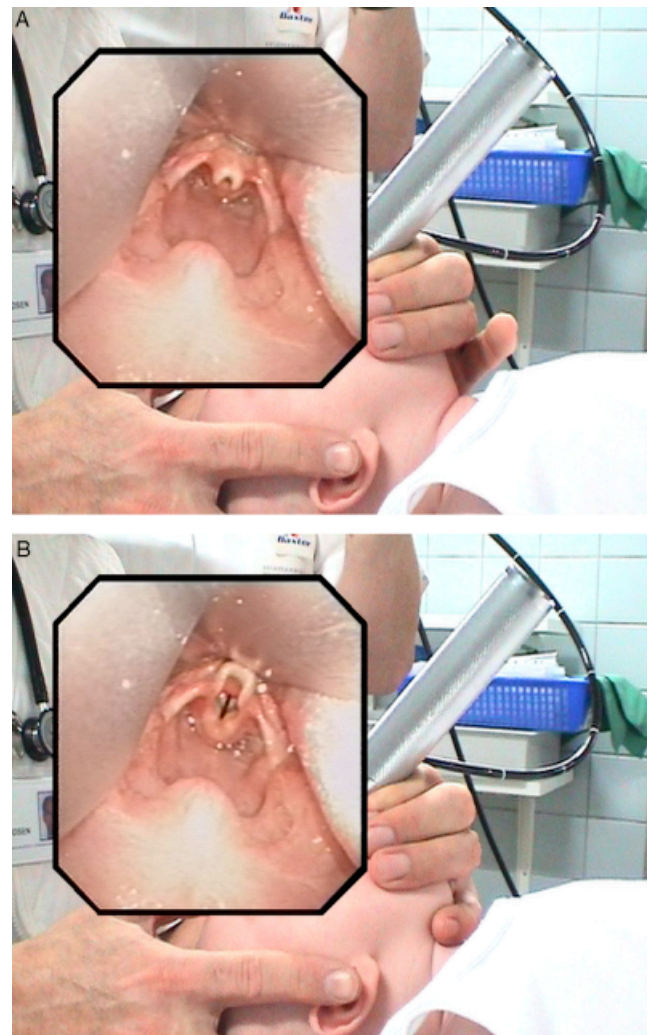

Fig. 4. (A) Glottic view without applying external pressure on the larynx. (B). Glottic view with a slight pressure on larynx with the fifth finger.

the same time listening for the breath sounds in the left axilla. When the breath sounds disappear, the tube tip would have reached the right main bronchus, after which it is retracted, until the sounds return. If the sounds do not disappear, the tube has entered the left main bronchus, and the procedure is repeated while listening in the right axilla.

In a few children, the intubation may be too difficult to allow you to manipulate and apply enough external pressure on the neck with the fifth finger. Instead of trying to instruct an assistant on how to manipulate and apply pressure on the neck, it is better to use both your hands to visualise the cords. When the view is, 'as good as it gets', keep the hands still, move your head out of the way, and let the assistant introduce the endotracheal tube (Fig. 5). This two-anaesthetist intubation is a very useful procedure, which has saved many days in both paediatric and adult practice. If, despite using this technique, only the epiglottis is seen, then fibre-optic intubation or 'look-around-corner-devices' should be considered.

Tracheal extubation

Before extubation, the child should be on spontaneous ventilation. Whether it should be performed during deep anaesthesia or in the awake state is probably a matter of preference, but it is also influenced by the actual circumstances. After airway surgery, if the anaesthesiologist has less paediatric experience, or if the airway was difficult to

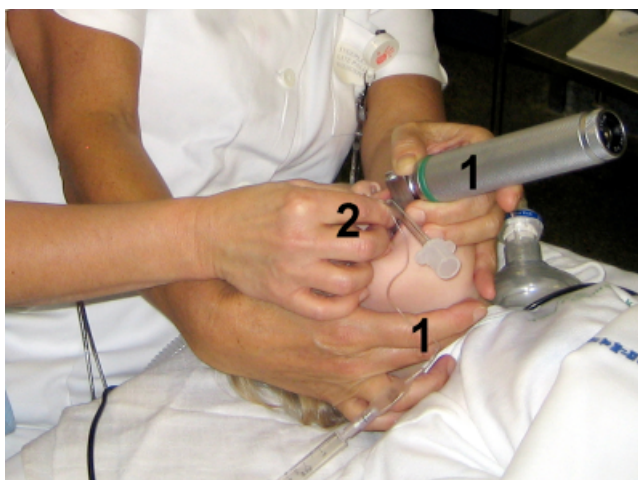

Fig. 5. Two-anaesthetist intubation. One person performs laryngoscopy and external manipulation of larynx to optimise the intubation condition, while a second person inserts the endotracheal tube.

handle during induction, extubating in the awake patient is preferable and associated with fewer airway complications such as laryngospasm.

A good extubation strategy is, before anaesthesia becomes too light, to turn the child on the side facing away from you, making it possible to stabilise the child against your body, and administer oxygen via a face mask after extubation if necessary. There should be no pillow under the head, making the trachea the uppermost part of the airway. In this way, secretions and blood will drain away from the larynx and run out the mouth.

Now leave the child completely undisturbed until ready for extubation. After sevoflurane anaesthesia, this is the case if the child makes purposeful movements or the expired concentration of sevoflurane is 0.3%. The circuit is filled with 100% oxygen and, without separating the anaesthetic circuit from the endotracheal tube, the extubation is performed during inspiration, while applying pressure on the ventilation bag. In this way, the child will receive a maximal inspiration just before extubation, and when the endotracheal tube leaves the trachea, the air will escape in a forceful expiration that will remove any residual secretions from the larynx. Use of this technique, while the child is lying on the side, makes suctioning before extubation unnecessary.

Airway oedema treatment

If the intubation turned out to be more difficult and traumatic than expected, it may be wise to administer intravenous (i.v.) steroids prophylactically to reduce the risk of airway oedema and post-intubation stridor. We suggest dexamethasone 0.6 mg/kg up to a maximum of 12 mg.

If stridor is present after extubation, adrenalin inhalation very effectively reduces the swelling. A rather high dose of L-adrenaline or racemic adrenaline can be used without significant side effects and our protocol includes L-adrenaline 0.5 mg/kg (maximum 6 mg). If racemic adrenaline is used the dose should be doubled. The treatment should be repeated at increasing intervals to avoid recurrence of the stridor.

Breathing a helium-oxygen mixture reduces the stridor instantaneously by lowering the viscosity of the air and may buy some time, until the effect of the steroids sets in. The helium concentration must be as high as possible and at least above 60% to have any clinical effect. Quite often, though, it is

difficult to 'persuade' the stressed and anxious child to breath the mixture, which is why reintubation may be the necessary and safest approach.

Laryngospasm

Laryngospasm consists of a powerful and prolonged contraction of the glottic and supraglottic laryngeal adductor muscles. The result is closure of the vocal cords and the false cords, and infolding of the arytenoid region, which effectively seals off the

larynx at three levels (Fig. 6). During complete laryngospasm it is not possible to force oxygen through the larynx or to intubate the child without injuring the airway. On the contrary applying excessive airway pressure may make the larynx work like a ball valve and thereby maintain the obstruction.

Laryngospasm is most commonly caused by secretions or blood in the airway during induction or awakening, but may also be elicited by systemic painful stimulation during maintenance, if the anaesthesia is too light.

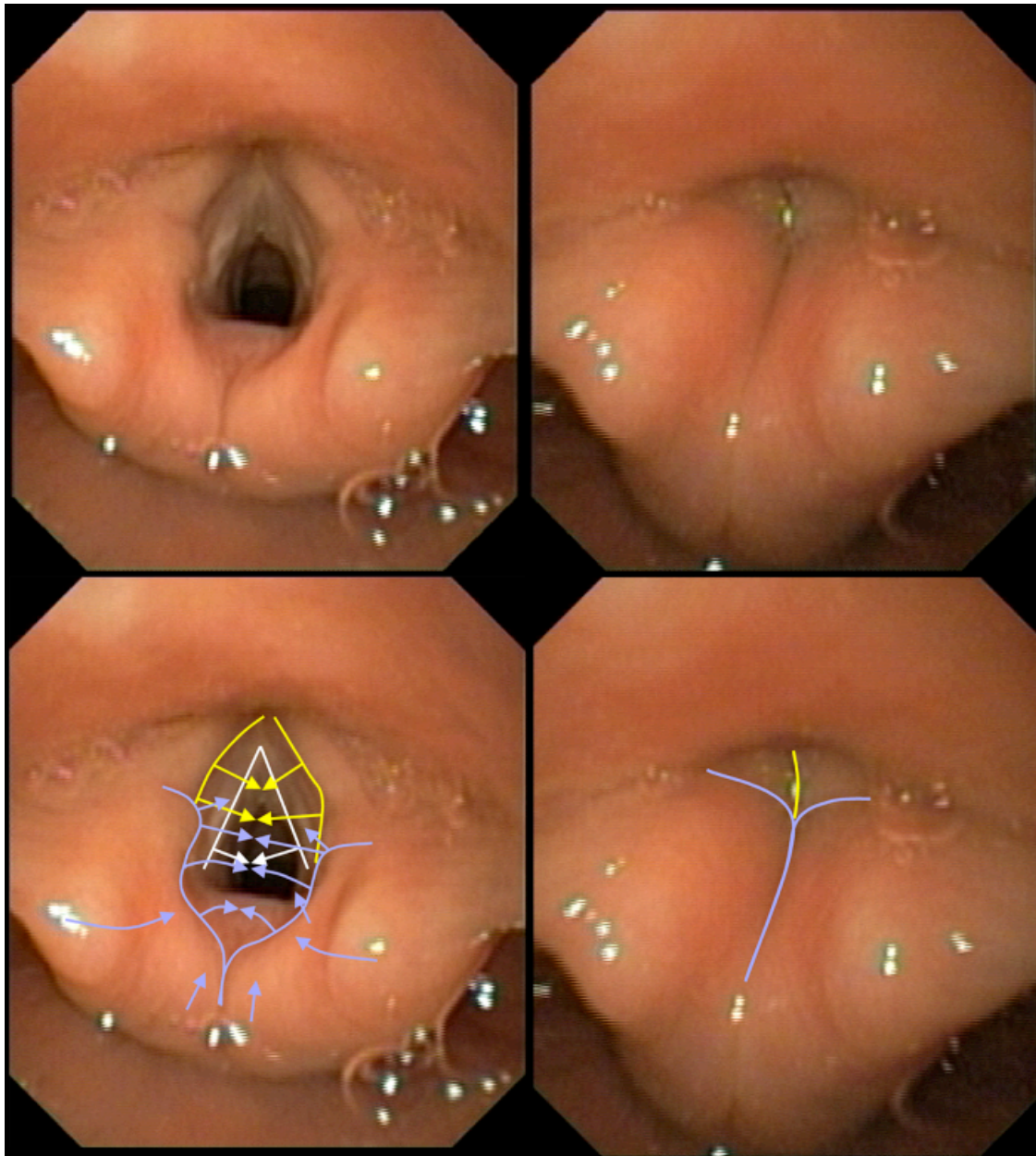


Fig. 6. Larynx before and during a laryngospasm. White, movement of the vocal cords; yellow, movement of false cords; blue, movement of arytenoids.

Several risk factors for laryngospasm have been identified (Table 4).^{7,8}

Even though the spasm will alleviate in the end due to hypoxia, it is not recommended to wait too long before interacting, as post-obstruction pulmonary oedema or even cardiac arrest may result.^{9,10}

If laryngospasm occurs, the first treatment should be oxygen delivered by a tight-fitting face mask applied with moderate intermittent pressure. If a high-pitched stridor is heard, it means that the spasm is partial and some oxygen can enter the lungs. A firm jaw-trust may stretch the larynx and help alleviate the spasm. During induction, an incomplete spasm will also allow anaesthetic gases to deepen the level of anaesthesia.

If the laryngospasm is complete, no air will enter the lungs, but oxygen should still be given by a face mask in order to be ready as soon the spasm alleviates. Propofol in small doses has been shown to alleviate the spasm in 75% of cases.¹¹ If it is ready in a syringe 1–2 mg/kg is given i.v., depending on whether the spasm occurs during induction or awakening. Otherwise, the most effective treatment is succinylcholine i.v. Doses as small as 0.1 mg/kg i.v. have been shown to relieve the spasm and 0.25–0.3 mg/kg i.v. will quickly relieve the spasm while allowing the child to continue spontaneous breathing.¹² Succinylcholine 4–5 mg/kg may be given intramuscularly if i.v. access has not yet been established. The site of injection should be central, i.e. in the pectoral or the deltoid muscle, followed by massage of the injection site. This will act rapidly, as the laryngeal muscles are very sensitive to the muscle relaxant, and only a small fraction has to be absorbed to alleviate the spasm.

Children with an increased risk of laryngospasm should be anaesthetised by experienced staff and a no-touch technique applied during recovery. Propofol 0.5 mg/kg given i.v. 60 s before extubation

Table 4

Risk factors for occurrence of laryngospasm.

Low age
Upper airway inflammation, actual or recently
Surgical procedure involving the airway
Exposure to smoking in the home
Anaesthetist with low experience in paediatric anaesthesia
Endotracheal intubation without use of muscle relaxant
Asthma
Thiopentone > sevoflurane > propofol for induction
Endotracheal intubation > LMA > face mask

LMA, laryngeal mask airways.

also reduces the risk.¹³ In small children, atropine may help by reducing secretions and attenuating vagal reflexes.

Conclusion

Paediatric airway management is a great challenge, especially for anaesthesiologists working in departments with a low number of paediatric surgical procedures. Strict adherence to safe and simple principles can definitely affect the confidence and outcome. It is essential to pay attention to the details described in this paper, such as positioning of the head of the child, keeping the mouth of the child open during mask ventilation, the appropriate use of supraglottic airways, and using an optimal technique during tracheal intubation and extubation.

Acknowledgement

Figures also appear in 'Børneanæstesi', edited by Tom G. Hansen and Steen W. Henneberg, FADL's forlag 2008. Text partly based on Danish chapter in that book.

References

1. Tay CLM, Tan GM, Ng SBA. Critical incidents in paediatric anaesthesia: an audit of 10 000 anaesthetics in Singapore. *Pediatr Anesth* 2001; **11**: 711–18.
2. Holm-Knudsen R, Eriksen K, Rasmussen LS. Using a nasopharyngeal airway during fiberoptic intubation in small children with a difficult airway. *Pediatr Anesth* 2005; **15**: 839–45.
3. Ghai B, Makkar JK, Bhardwaj N, Wig J. Laryngeal mask airway insertion in children: comparison between rotational, lateral and standard technique. *Pediatr Anesth* 2008; **18**: 308–12.
4. Wahlen BM, Heinrichs W, Latorre F. Gastric insufflation pressure, air leakage and respiratory mechanics in the use of the laryngeal mask airway (LMA™) in children. *Pediatr Anesth* 2004; **14**: 313–7.
5. Park C, Bahk JH, Ahn WS, Do SH, Lee KH. The laryngeal mask airway in infants and children. *Can J Anaesth* 2001; **48**: 413–7.
6. Khine HH, Corddry DH, Ketrack RG, Martin TM, McCloskey JJ, Rose JB, Theroux MC, Zagnoev MMB. Comparison of cuffed and uncuffed endotracheal tubes in young children during general anesthesia. *Anesthesiology* 1997; **86**: 627–31.
7. Mamie C, Habre W, Delhumeau C, Argiroffo CB, Morabia A. Incidence and risk factors of perioperative respiratory adverse events in children undergoing elective surgery. *Pediatr Anesth* 2004; **14**: 218–24.
8. Skolnick ET, Vomvolakis MA, Buck KA, Mannino SF, Sun LS. Exposure to environmental tobacco smoke and the risk of adverse respiratory events in children receiving general anesthesia. *Anesthesiology* 1998; **88**: 1144–53.

9. Olsson GL, Hallen B. Laryngospasm during anaesthesia. A computer-aided incidence study in 136 929 patients. *Acta Anaesthesiol Scand* 1984; **28**: 567–75.
10. Alalami AA, Ayoub CM, Baraka AS. Laryngospasm: review of different prevention and treatment modalities. *Pediatr Anesth* 2008; **18**: 281–88.
11. Afshan G, Chohan U, Qamar-Ul-Hoda M, Kamal RS. Is there a role of a small dose of propofol in the treatment of laryngeal spasm? *Pediatr Anesth* 2002; **12**: 625–8.
12. Chung DC, Rowbottom SJ. A very small dose of suxamethonium relieves laryngospasm. *Anaesthesia* 1993; **48**: 229–30.
13. Batra YK, Ivanova M, Ali SS, Shamsah M, Al Qattan AR, Belani KG. The efficacy of a subhypnotic dose of propofol

in preventing laryngospasm following tonsillectomy and adenoidectomy in children. *Pediatr Anesth* 2005; **15**: 1094–7.

Address:

Rolf J. Holm-Knudsen

Department of Anaesthesia

Center of Head and Orthopaedics

Copenhagen University Hospital

HOC 4231, Rigshospitalet

Blegdamsvej 9

DK-2100, Copenhagen

Denmark

e-mail: rhk@rh.dk